

TJHSST Computer Systems Lab Senior Research
Project
Automating Scoliosis Analysis
2008-2009

Amar Sahai

April 2, 2009

Abstract

My program will analyze a spinal x-ray for scoliosis in two phases. It will first take a spinal x-ray image file and detect the edges of the spine, isolating it from the rest of the x-ray. Then, that image is inputted into another program which can automatically measure the angles of curvature and points at which to apply pressure for optimum treatment. This second part of the program will have a GUI to allow manual user input as well.

Keywords: edge detection

1 Introduction

Scoliosis, or lateral curvature of the spine, is a health defect that starts showing signs often in early adolescence. Early and accurate diagnosis of this condition is most help-

ful in preventing its growth, and thus preventing the need for spinal surgery. One of the current processes to treat the curve is to manually measure the angles of the patient's curve(s) and then determine pressure points.

My program will operate in two phases. The first phase will take an x-ray image file and execute certain algorithms on it to remove parts unnecessary or hindering spinal analysis. The second phase will take the input from the first phase and automatically measure the angles and points at which to apply pressure for optimum treatment and return this image to the user (presumably a doctor). This will make optimum treatment of scoliosis a partially automated (and thus much easier) process for both the doctor and the patient.

2 Background

People have tried different approaches to problems similar to the one I am working on. For example, one group of researchers used moir images of patients. backs to detect if they had scoliosis. The program, in the end, had an 88.2 percent rate of accuracy. This tells me that using moir images could be one approach to my problem as well. If I can find out how the authors detected scoliosis through the images, I could perhaps convert the x-ray to one and make more observations from the same findings.

The primary approach I have used to solve my problem so far is edge detection. I have mostly been using two specific edge detection algorithms: horizontal differencing and Robert's cross. In horizontal differencing, edge are determined by contrast from horizontally adjacent pixels.

3 Development

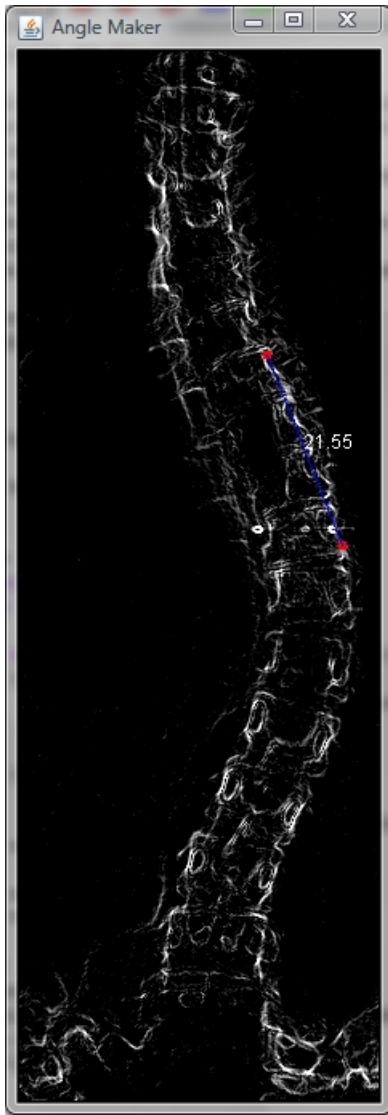
So far, the primary approaches I have used for the first phase of my program are edge detection by horizontal differencing and with the Robert's cross algorithm. Since these approaches have been mainly unsuccessful, I plan on trying simpler methods to achieve the same goal. Instead of attempting to trace out the spine with edge detection, I will simply remove the ribcage from the picture and then find the rightmost and leftmost points. These will be the points at which the spine curves and thus where pressure should be applied for optimal treatment. Another feature

I could add to my program is calculating the angles of curvature. I would use this by approximating edge detection and then measuring the angle between the two resulting lines.

In the second phase, I use edge detection for my semi-automatic detection mode. The edge detection I used in this phase was previously a crude approximation. It searched for the brightest pixel in a certain size square centered at the mouse and used that as the point to click on for creating a line to determine an angle.

Now I have implemented the Sobel edge detection method into Phase 2 of my program. This algorithm is significantly more accurate. It uses "masks" to determine gradients for each pixel. Any pixel with a high enough G value is recorded as an edge.

The input my program takes is the x-ray in a .pgm picture file format. In order to test my program, I just input the .pgm file I currently have and examine the final output using GIMP to view it. For the second phase of my program, I convert the output from the first phase to a .gif and use that as the input. To test the second phase, I simply open the program and test the features a user would use.



- [2] Mira Park, et al., "Detection and Measurement of Hilar Region in Chest Radiograph"
- [3] David A. Levine, et al., "Automatic Computer Recognition and Analysis of Dental x-ray Film"

A screenshot of the manual mode of Phase 2.

References

- [1] Ken Brodlie, et al., "Using Web-Based Computer Graphics to Teach Surgery"